



*Human eye, optic nerve,  
3D-visualization, direct volume rendering,  
optic disc*

Cornelia KOBER<sup>1</sup>, Britt-Isabelle BÖRNER<sup>2,3</sup>, Carlos BUITRAGO TELLÉZ<sup>4</sup>,  
Markus KLARHÖFER<sup>5</sup>, Klaus SCHEFFLER<sup>5</sup>, Ernst Wilhelm RADÜ<sup>6</sup>,  
Hans-Florian ZEILHOFER<sup>2,3</sup>

## **FIRST ATTEMPTS FOR SEMIAUTOMATIC 3D-VISUALIZATION OF THE OPTIC NERVE**

This paper is dedicated to a new (but not yet fully matured) semiautomatic approach of visualization of the optic nerve based on MRI data stemming from the clinical practice. Position and condition of the optic nerve can be recognized. Besides further improvement of this approach, dynamical visualization of moving optic nerve based on a time dependent series of MRI data sets is subject of actual research.

### **1. INTRODUCTION**

The human eye (see Fig. 1) is one of the most essential organs for the quality of life. Malfunction of this organ due to trauma or disease is subject of detailed research. The standard approach for 3D-rendering of human anatomy is segmentation together with 3D-surface reconstruction. Segmentation consists in reduction of the considered images to binary data separated into black and white according to a user defined strategy. If tissue differentiation is enough clear, as for bony organs in CT data for instance, shaded surface reconstruction is of generally accepted benefit. But, as regards the optical nerve in MRI, the inherent spatial information is very scarce. Further, exact tissue classification is unclear. This renders segmentation tedious, error-prone, and highly user dependent. Therefore, the purpose of this article is an alternative approach.

### **2. METHODS**

The analysis was performed based on an 3D-MRI data set of a healthy volunteer (female, 28 Y) comprising 56 axial slices each with isotropic voxel size of 1 mm in x, y, and z-direction (Siemens, 1.5 T, SE imaging sequence). The eyes were oriented to the left (see Fig 2 a).

---

<sup>1</sup>Faculty of Engineering and Computer Science, University of Applied Science Osnabrueck, Osnabrueck, Germany.

<sup>2</sup>Hightech Research Center of Cranio-Maxillofacial Surgery, University Hospital Basel, Switzerland

<sup>3</sup>Dept. of Cranio-Maxillofacial Surgery, University Hospital Basel, Switzerland

<sup>4</sup>Dept. of Neurology, University Hospital Basel / Radiological Center Aarau Zofingen, spitalzofingen AG, Switzerland

<sup>5</sup>MR Physics, University Hospital Basel, Switzerland

<sup>6</sup>Dept. of Neuroradiology, University Hospital Basel, Switzerland

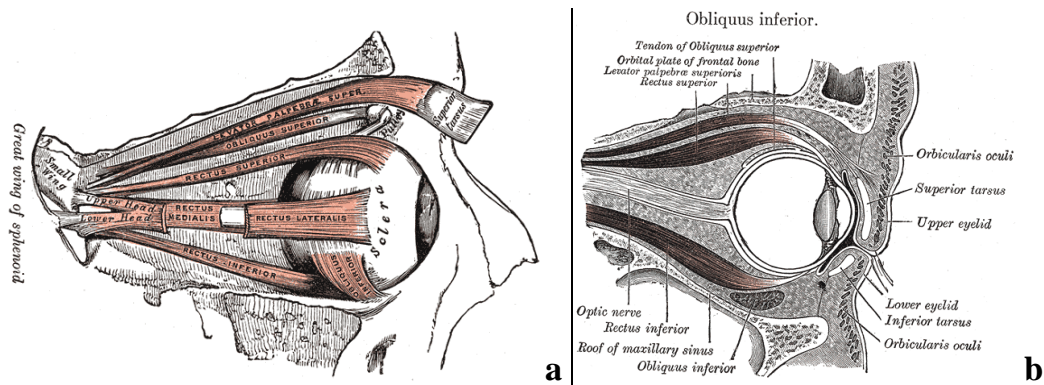


Fig.1 Anatomy of the human eye [2], muscles of the right orbit, sagittal view (a), sagittal section of right orbital cavity (b)

As a first step within visualization, the dominant bulb was first segmented by threshold segmentation and then subtracted from the MRI data set. For the second step, the modified MRI data set was subjected to direct volume rendering which is one of the most intuitive and most powerful techniques for visualizing 3D image data. Light emission and light absorption parameters are assigned to each point of the volume. Simulating the transmission of light through the volume makes it possible to display your data from any view direction without constructing intermediate polygonal models [1, 3]. For the sake of clear visibility of the anatomy, a temperature colour scale was applied ranging from dark blue – low grey values over red colour to yellow colour – high grey values (see Fig 2 b-d) The direct volume rendering of the MRI data was superposed with the original MRI slices also transparently rendered (see Fig 2b). By the reduced grey values of the bone corresponding to dark blue colour, the skull could be differentiated from the muscular tissue by visual inspection. Thereby, it was possible to iteratively isolate the optical cavity by interactive modification of the 3D image data (see Fig. 2c). The removed voxels were replaced by zero grey value. Finally, the remaining data set was cropped and resampled to a resolution of 0.5 mm in each spatial direction. The volume rendering of the result inter alia provides a visualization of the optical muscles (see Fig 2d). By this processing, the frontal visualization of the optic disc given in Fig. 3 is possible.

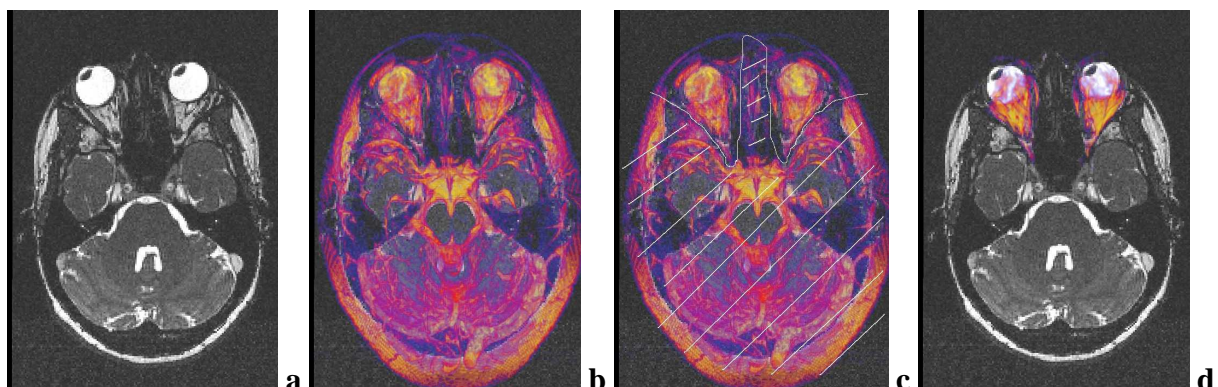
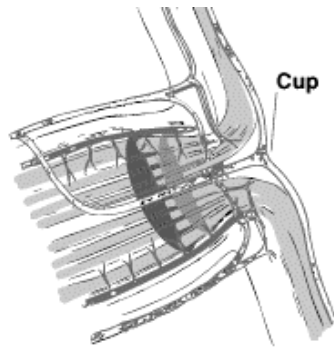


Fig.2 Original axial MRI slice (a), direct volume rendering (temperature colour scale) of the MRI data set with transparently rendered MRI slice (b), interactive modification of the 3D image data: the grey values of voxels in the hatched volume were replaced by zero (c), final result: axial MRI slice superimposed with direct volume rendering of the remaining voxels after interactive modification of MRI data (d)

For the visualization of the optical nerve characterized by lower grey values compared to the muscular tissue, the modified MRI data set was inverted which means that the grey values were subtracted from the maximal grey value within the modified MRI set (step 3 of the procedure). By this, high grey values were turned to low grey values (now yellow colour) and vice versa. After this, Gaussian flattening was applied. Again the modified MRI data were subjected to direct volume rendering using a temperature colour scale. For the sake of anatomical orientation, the eye balls were visualized as shaded surfaces. By axial or sagittal clipping of the visualization, the optical cavity could be "opened" and the optic nerve was visible.

The geometry reconstructions from 3D image data and all visualizations were performed by means of the visualization toolbox Amira 4.0 [1,3]. Finally, automation of the procedure is expected to be possible with acceptable programming efforts.

## 2. RESULTS AND OUTLOOK



Head of Optic Nerve

Fig. 3 Anatomy of the head of the optic nerve [4]

The visualizations given in Fig. 4-6 provide a 3D-impression of the position and condition of the optic disc, see Fig. 3 for an overview of the anatomy, as well as of the optical nerve (both in yellow colouring). Partially, it is also possible to recognize the medial rectus muscle (see Fig. 6). Notably, though both eyes were oriented to the left the positions of the left respectively the right optic nerve are not symmetric (see Fig. 5). As an outlook to ongoing research, dynamical visualization of moving optic nerve based on a time dependent series of MRI data of the optic nerve should be mentioned.

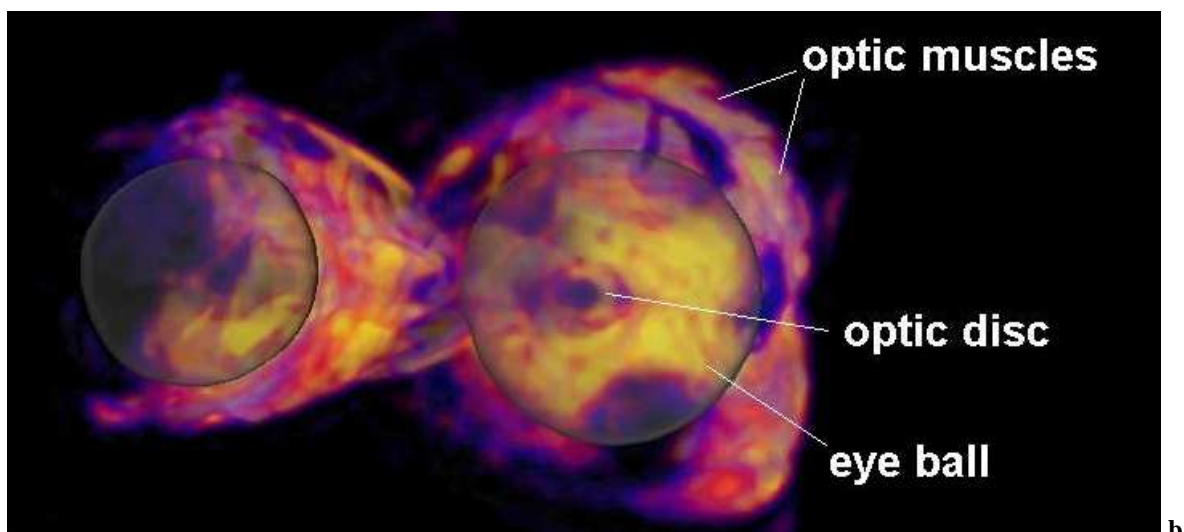


Fig.4 Visualization of the optic disc with the eye ball in transparent rendering

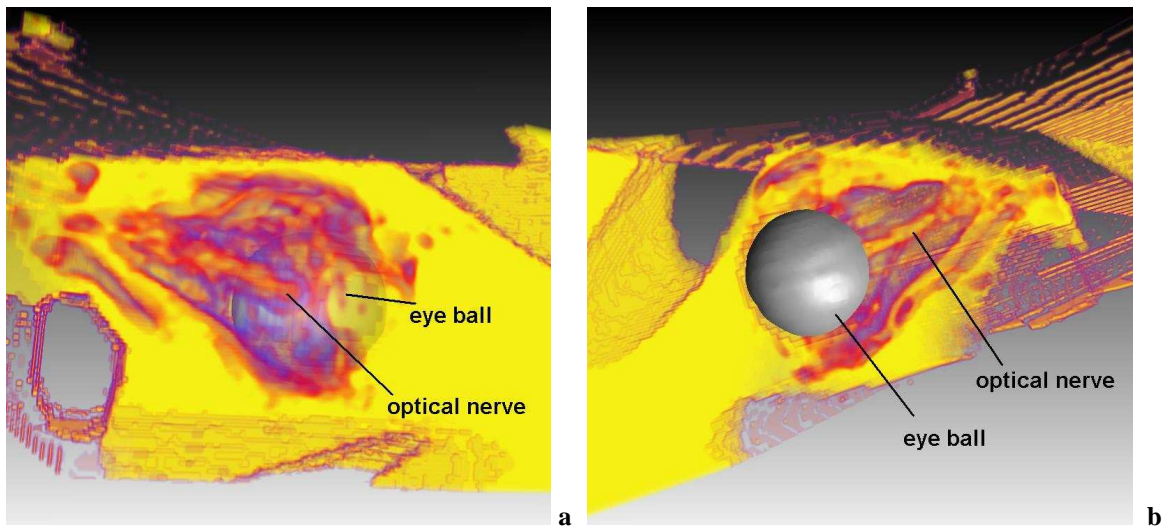


Fig. 5 Visualization of the optical nerve, right eye from behind (a), left eye (b) by means of oblique sagittal clipping, the eye balls are in shaded rendering

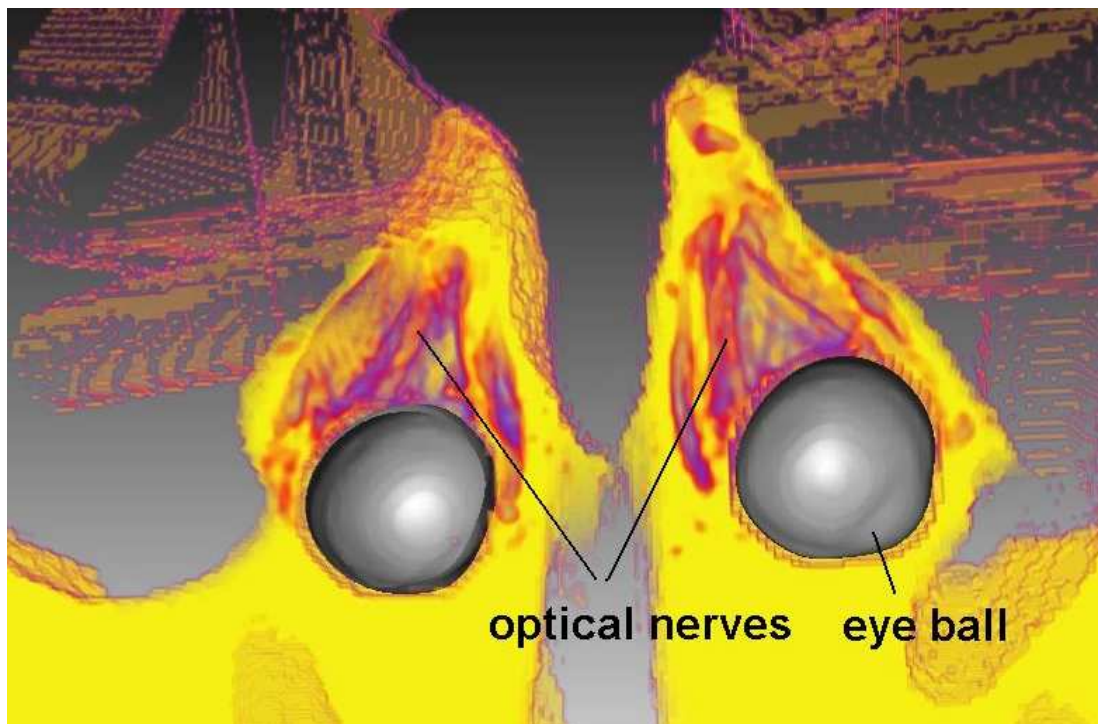


Fig. 6 Visualization of the optical nerve by means of axial clipping, partially the rectus muscle can be seen, the eye balls again in shaded rendering

#### BIBLIOGRAPHY

- [1] Amira – Advanced 3D Visualization and Volume Modeling, [www.amiravis.com](http://www.amiravis.com)
- [2] Gray, H., Anatomy of the Human Body, <http://www.bartleby.com/107/>
- [3] Stalling, D., Westerhoff M., Hege, H.-C., Amira: A Highly Interactive System for Visual Data Analysis. The Visualization Handbook (ed. Hansen C. D., Johnson C. R.), No. 38, pp. 749-67, Elsevier, 2005.
- [4] UCL Institute of Ophthalmology, Eye Science, [www.ucl.ac.uk/ioo/eyescience.htm](http://www.ucl.ac.uk/ioo/eyescience.htm)